



Urinary Tract Infections: Investigation and Follow up

Aim

This guideline provides an evidence-based framework for the investigation and follow up of children following a urinary tract infection (UTI), referred to the Department of General Paediatrics (DGP) at Princess Margaret Hospital (PMH).

Background

Urinary tract infections (UTIs) are common. UTIs can lead to renal scarring and renal dysfunction or hypertension in adulthood. Abnormalities of the renal tract may predispose children to developing UTIs.

The management of UTI has changed in the past decade, with improvement in renal imaging modalities and recognition that past practices have been based on limited evidence.

Initial Management

Children aged greater than 3 months presenting to PMH with a UTI should be initially managed in accordance with the Emergency Department UTI guideline.

- [PMH Emergency Department Guidelines](#)

Febrile infants less than 3 months of age should be managed according to the Emergency Department fever without focus guideline.

- [PMH Emergency Department Guidelines](#)

Antibiotic therapy should be commenced in accordance with the ChAMP antimicrobial guidelines.

- [ChAMP Empiric Guidelines: Urinary Tract Infections](#)

Investigations

Renal Tract Ultrasound (US)

Renal tract ultrasound is used to assess renal anatomy.

For children less than 3 years of age;

- A renal tract US for all children following their first UTI is recommended.
- Children with an atypical UTI or UTI responding poorly to treatment should have a renal tract US performed acutely, ideally during their hospital admission.¹
- All other children should have a renal tract US performed on a non – urgent schedule.

Children aged 3 years or older;

A renal tract ultrasound is not always necessary for older children with a simple UTI, however:

- Children of any age with recurrent UTIs should have a renal tract US (non urgent).
- Children of any age with an atypical UTI or UTI responding poorly to treatment should have a renal tract US (urgent).¹

Micturating Cystourethrogram (MCUG)

MCUG provides an assessment of renal tract anatomy during voiding. Its purpose is to detect renal tract obstruction, anatomical anomalies and vesico-ureteric reflux (VUR).

Routine MCUG is no longer recommended after all first UTI. A recent audit performed within our institution found that a renal tract US performed by the PMH radiology service effectively excluded high grade (4 or 5) VUR and posterior urethral valves (n = 220).² Good quality renal tract US may obviate the need for MCUG.

MCUG should be considered if;

- The renal tract US is abnormal (with features suggestive of VUR / obstruction, scarring, or poor growth)
- In atypical UTIs
- If there is a history of poor urine flow
- If there is a family history of VUR³

Dimercaptosuccinic Acid Scan (DMSA Scan)

DMSA scans are used to assess renal function. DMSA scans show areas of differential uptake of a radioisotope in the kidney. This differential uptake is presumed to be due to renal injury or scarring. DMSA scans are usually performed 4 to 6 months following acute infection.

Recent literature suggests that some scarring detected on DMSA may pre-exist the UTI. The long term outcome and prognosis of renal scarring detected on DMSA is unclear. There is no consensus within the literature as to how renal scarring should be monitored.

DMSA scans have been recommended for children up to the age of 3 years with atypical or recurrent UTI. For children greater than 3 years of age, DMSA scan is only recommended for recurrent infections.⁴

A recent audit performed within our institution found that a normal renal tract US performed by the PMH radiology service excluded significant abnormalities on DMSA with a negative predictive value of 90% (n = 143). Of those children who had a normal ultrasound and abnormal DMSA scan, 4/9 had a small single renal scar with normal differential function, and 5/9 had no scar but borderline differential function (4/5 were 44% vs. 56% and 1/5 was 43% vs. 57%).⁵

Repeat renal tract US may be an acceptable alternative to DMSA for monitoring renal scarring.

Mercaptoacetyltriglycine Scan (MAG 3 Scan) or Diethylene Triamine Pentacetic Acid Scan (DTPA Scan)

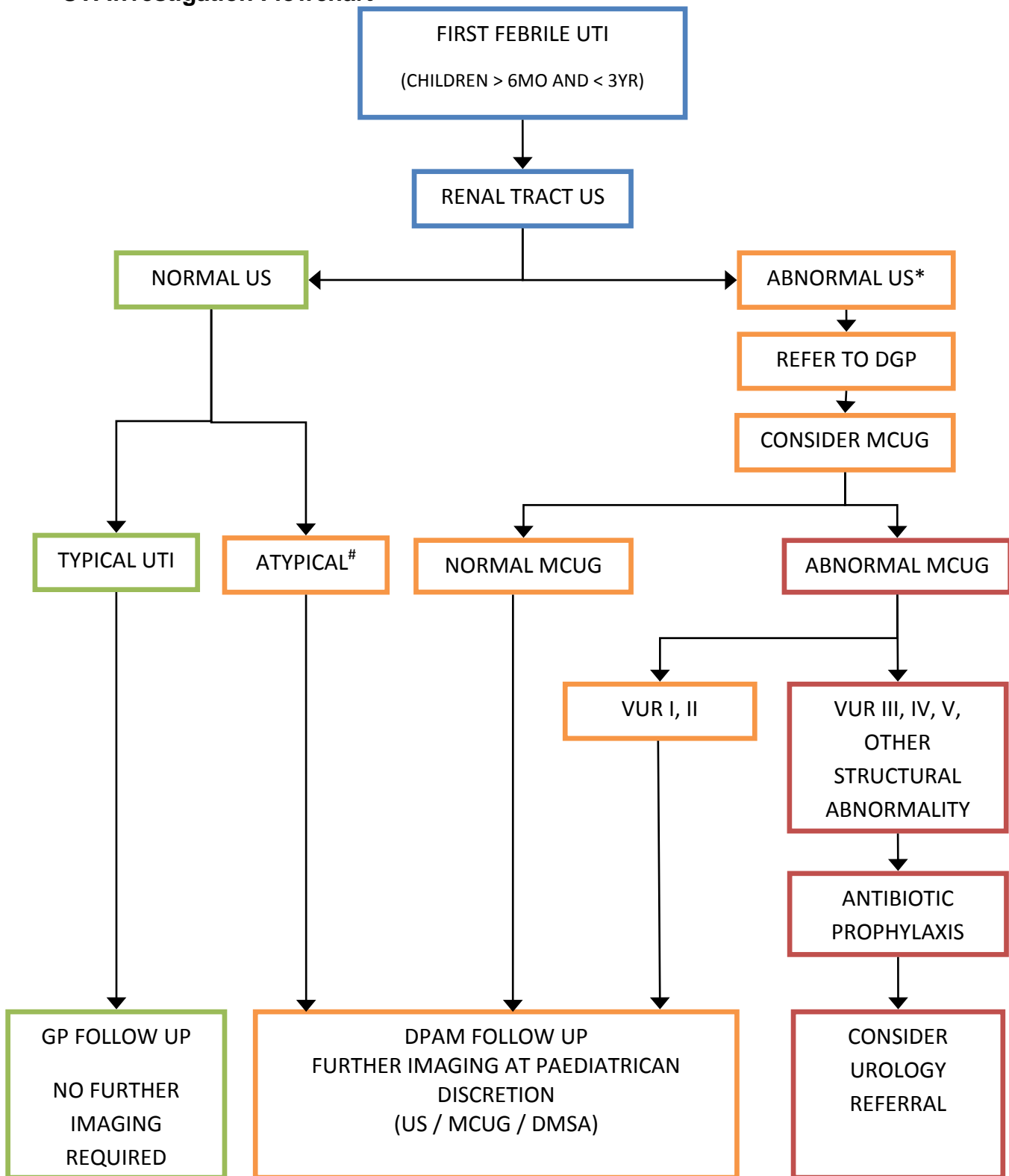
MAG 3 and DTPA studies provide information on differential renal function and drainage. MAG 3 and DTPA scans can be used to make some assessment of cortical abnormality however a DMSA scan is a superior study for this purpose. MAG 3 and DTPA scans can be used to assess for VUR however they are less sensitive than MCUG.

MAG 3 and DTPA studies are typically used for children in whom obstruction may be suspected. In older children where MCUG is undesirable due to age and discomfort, MAG 3 or DTPA can be used to provide an assessment of VUR.

Investigation Pathways

- Children less than 6 months old should have a renal tract US and be referred to a Paediatrician for follow up and consideration of the need for further investigation.
- Children aged 6 months – 3 years who have a normal renal tract US after their first uncomplicated UTI can be followed up by their GP.
- Children greater than 3 years with their first uncomplicated UTI do not necessarily need further investigation. These children can be followed up by their GP.
- Children who have a history of recurrent UTI, a family history of VUR or known renal abnormalities may require further imaging such as a MCUG or DMSA. These cases should be discussed with their treating Paediatrician.

UTI Investigation Flowchart




***Abnormal US** - refers to an US that suggests renal tract obstruction or scarring or discrepancy in size. If the US shows changes suggestive of acute pyelonephritis (such as kidney size > 97th percentile), follow up with a repeat US rather than MCUG is recommended.

Atypical UTI – refers to a UTI caused by a non E coli organism, UTI with septicaemia, UTI with poor response to treatment within the first 48 hours, UTI in association with poor urine flow, abdominal mass or raised creatinine.

References

1. CG54 Urinary tract infection in children: full guideline, 22 August 2007 National Institute for Health and Care Excellence (NICE) (<http://www.nice.org.uk/nicemedia/live/11819/36028/36028.pdf>), Reviewed October 2013.
2. Leung M, Ozanne R, Smith L, Martin AC. Utility of Screening Ultrasound After First Febrile UTI Among Patients With Clinically Significant Vesico-ureteral Reflux. Urology 2014 (in press)
3. CG54 Urinary tract infection in children: full guideline, 22 August 2007 National Institute for Health and Care Excellence (NICE) (<http://www.nice.org.uk/nicemedia/live/11819/36028/36028.pdf>), Reviewed October 2013.
4. CG54 Urinary tract infection in children: full guideline, 22 August 2007 National Institute for Health and Care Excellence (NICE) (<http://www.nice.org.uk/nicemedia/live/11819/36028/36028.pdf>), Reviewed October 2013.
5. Tan A, Troedson R, Martin AC. A normal Renal Ultrasound Scan reliably excludes major abnormalities on DMSA in children with UTIs. J Paed Child Health 2014 (in press).

| | | | |
|---|---|--------------|-----------|
| File Path: | W:\Safety & Quality\CAHS\CLOVERS Nursing Infection Control\Paediatric Nursing Practice Manual\PMH Clinical Practice Guidelines_Word\PMH.CPG.UrinaryTractInfections.doc | | |
| Document Owner: | Department of General Paediatrics (DGP) | | |
| Reviewer / Team: | Dr Ciara Peake, Dr Aggie Judkins, Dr Andrew Martin (DGP) | | |
| Date First Issued: | 1/9/2014 | Version: | 1 |
| Last Reviewed: | 1/9/2014 | Review Date: | 1/9/2017 |
| Approved by: | Dr Louise Houliston, HOD, DGP | Date: | 4/11/2014 |
| Endorsed by: | Medical Advisory Committee | Date: | 9/12/2015 |
| Document Sponsor: | Dr Gervase Chaney, Chair, PMCCU | | |
| Standards Applicable: | NSQHS Standards:  | | |
| The accuracy of this document is not guaranteed when printed | | | |